

EFFICACY EVALUATION OF A DERMOCOSMETIC WITH SKIN REPAIR PROPERTIES AFTER FRACTIONAL LASER SURGERY IN ACNE SCARS

Qian Zhang¹, Dong Zhang¹, Li Wang¹, Rongli Zhang¹, Jingyi Wei¹, Lin Gao¹, Xianghua Zhang², Delphine Kerob³, Zhongxing Zhang²

¹Department of Dermatology, Xijing Hospital, Fourth Military Medical University, Xi'an, China, ²La Roche-Posay Laboratoire Dermatologique, Shanghai, China, ³La Roche-Posay Laboratoire Dermatologique, Levallois-Perret, France

INTRODUCTION

Acne scars are the cause for a significant morbidity among dermatology out-patients.¹ Insights in the potential of fractional laser treatments have established standard laser procedures to treat acne scars.²

Non-ablative fractional 1565 nm laser therapy is indicated in the reduction of pore size, acne scars, wrinkles and photoageing. However, it also causes a series of changes in skin and soft tissues, such as erythema, swelling, pain, burning and other discomfort.^{3,4}

The recovery period and potential side effect of post fractional laser may be important, post-laser care using dermocosmetics (DC) is highly indicated to increase the outcome of laser procedures.^{5,6}

OBJECTIVES

This study evaluated the clinical efficacy and safety of a DC balm in the skin repairing process after fractional laser therapy in acne scars.

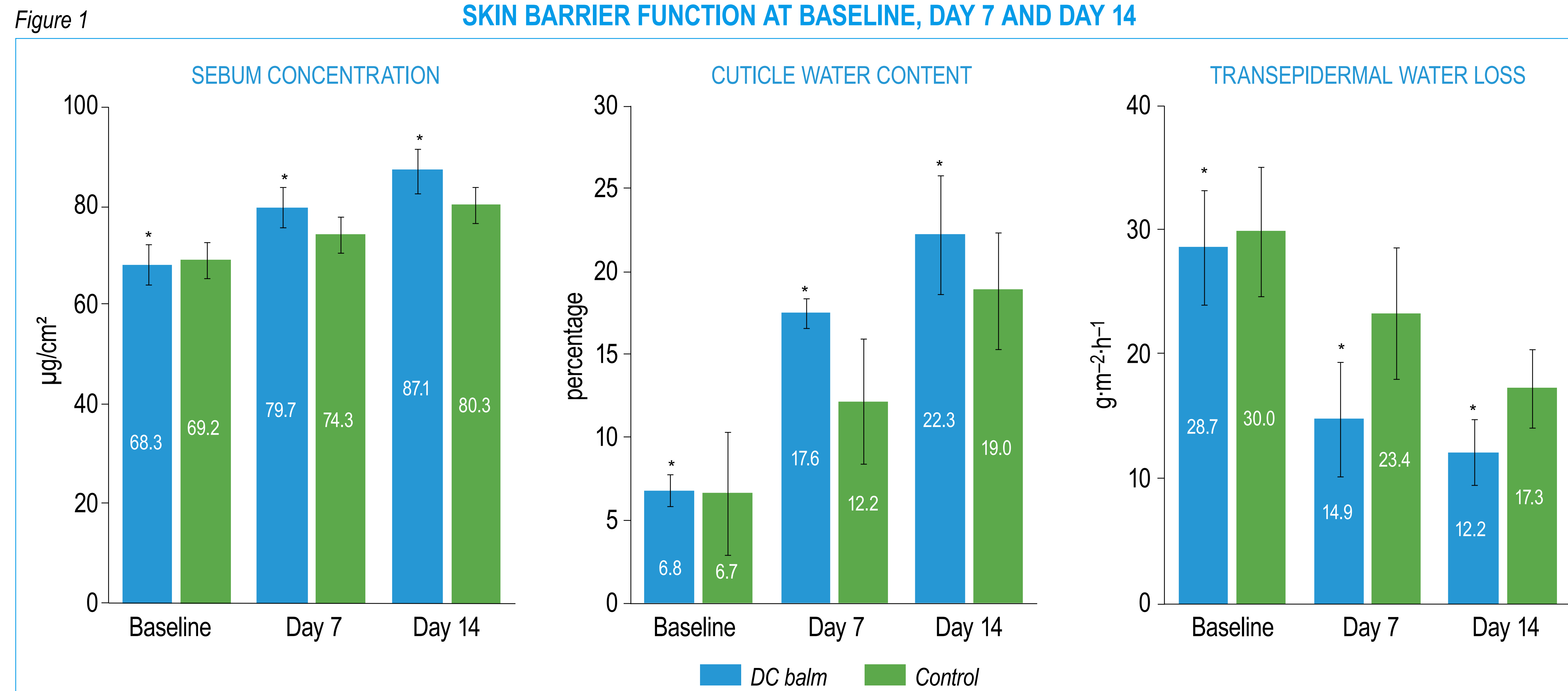
RESULTS

Subjects were aged between 24 and 50 years with a mean age of 39.5±8.6 years. The control group (40.03±12.65 years) was somewhat older than the DC balm group (38.76±14.09 years).

14 days after the procedure, the total effective rates of the DC balm and the control group were similar (97.6% and 92.9%, respectively). 14 days after the procedure, SC and CWC levels in the DC balm group were significantly ($p<0.001$) higher than in the control group (SC: 87.11±4.4µg/cm² vs 80.29±3.52 µg/cm² CWC: 22.31±3.62% vs 18.95±3.15%; Figure 1).

Conversely, the TEWL in the DC balm group was significantly less important than in the control group (14.94±3.62 g·m⁻²·h⁻¹ vs 23.38±4.04 g·m⁻²·h⁻¹, $p<0.001$); a significant improvement was observed as early as after 7 days (Figure 1). After 7 and 14 days of use, the erythema and melanin index were significantly (all $p<0.05$) lower in the DC balm than in the control (Figure 2). The incidence of post-laser complications was significantly ($p<0.035$) higher in the control (23.8%) than in the DC balm group (7.1%).

SKIN BARRIER FUNCTION AT BASELINE, DAY 7 AND DAY 14



The difference between the DC balm and the control regimen was statistically significant ($p<0.001$) for all parameters at both post-baseline visits in favour of the DC balm.

MATERIALS & METHODS

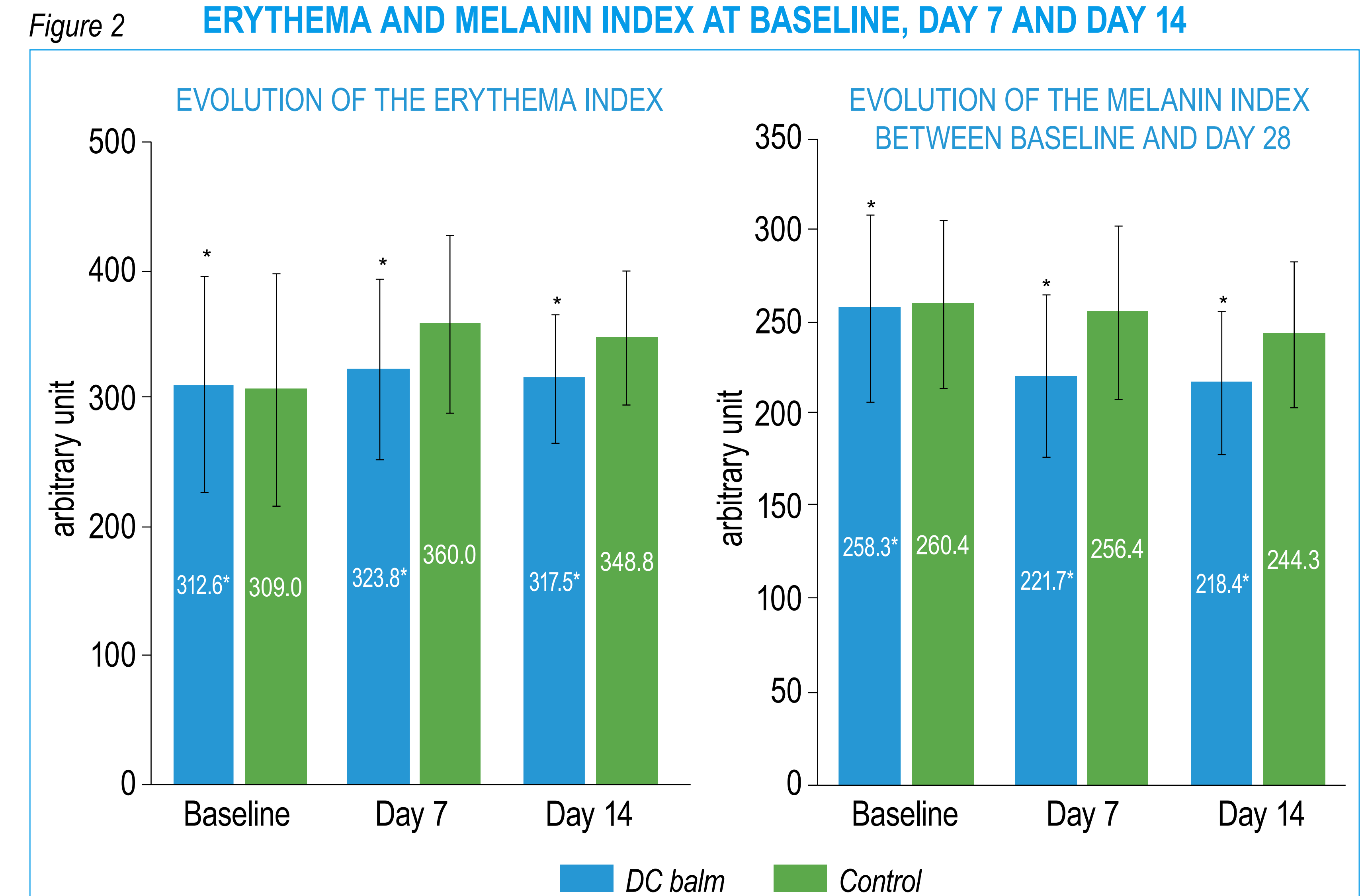
84 adults (76 women, 8 men) who underwent acne scar fractional laser were included in this open label study. The population was equally randomized into an active group receiving the DC balm and control group receiving a routine facial care.

The sebum content (SC), cuticle water content (CWC) and transepidermal water loss (TEWL) were measured using instrumental means on the 1st day before the procedure (Baseline), on the 7th day after the procedure (Day 7) and 14th day after the procedure (Day 14), respectively.

The lesional erythema and melanin index was assessed using a skin image analyzer.

The occurrence of post-laser complications within 14 days after the procedure was recorded.

ERYTHEMA AND MELANIN INDEX AT BASELINE, DAY 7 AND DAY 14



The difference between the DC balm and the control regimen was statistically significant ($*p<0.05$) for erythema and the melanin index at both post-baseline visits in favour of the DC balm.

CONCLUSION

The post-laser application of a specifically developed dermocosmetic balm for 14 days improves skin hydration, reduces procedure-related complications, and promotes the early recovery of skin damage after fractional laser operation of acne scars.

References

1. Tan J, Beissert S, Cook-Bolden F, Chavda R, Harper J, Hebert A, et al. Impact of Facial Atrophic Acne Scars on Quality of Life: A Multi-country Population-Based Survey. *Am J Clin Dermatol.* 2022;23(1):115-23.
2. Sadick NS, Cardona A. Laser treatment for facial acne scars: A review. *J Cosmet Laser Ther.* 2018;20(7-8):424-35.
3. Alexis AF, Coley MK, Nijhawan RI, Luke JD, Shah SK, Argobi YA, et al. Nonablative Fractional Laser Resurfacing for Acne Scarring in Patients With Fitzpatrick Skin Phototypes IV-VI. *Dermatol Surg.* 2016;42(3):392-402.
4. Degitz K. [Nonablative fractional lasers: Acne scars and other indications]. *Hautarzt.* 2015;66(10):753-6.
5. Guerrero D. Dermocosmetic management of hyperpigmentations. *Ann Dermatol Venereol.* 2012;139 Suppl 4:S166-9.
6. Fabbrocini G, Rossi AB, Thouvenin MD, Peraud C, Mengeaud V, Bacquey A, et al. Fragility of epidermis: acne and post-procedure lesional skin. *J Eur Acad Dermatol Venereol.* 2017;31 Suppl 6:3-18.

Funding: This study was funded by La Roche-Posay Laboratoire Dermatologique, China.

Acknowledgments: The authors acknowledge the editing assistance of Karl Patrick Göritz, SMWS France and the art work of Dominique Poisson, France.